



Biatain Soft-Hold

Product ordering information

For product availability please contact your local Coloplast office or distributor.

Find contact information at www.coloplast.com

Coloplast®, Biatain® are registered trademarks of Coloplast A/S or related companies.
© 2008/03. All rights reserved Coloplast A/S, 3050 Humlebæk, Denmark

Biatain Soft-Hold

CASE STUDY

Two weeks treatment of a moderately exuding venous leg ulcer with **Biatain Soft-Hold Foam Dressing**

CASE STUDY

Two weeks treatment of a moderately exuding venous leg ulcer with **Biatain Soft-Hold Foam Dressing**

Authors: **Haase L, Vogensen H, Vorbeck L & Jørgensen B.**

Copenhagen Wound Healing Centre, Bispebjerg University Hospital, Copenhagen, Denmark

INTRODUCTION

This report describes a patient suffering from a venous leg ulcer with underlying oedema during a two weeks treatment with **Biatain Soft-Hold**: One week using the new, improved **Biatain Soft-Hold** followed by one week using the former version of **Biatain Soft-Hold**. Both dressings were used in combination with compression therapy.

The prevalence of leg ulcers rises with increasing age. Approximately 3-5% of elderly people suffer from chronic leg ulcerations¹. In addition, leg ulcers are commonly a disease of long duration with significant costs and a negative impact on the patient's quality of life^{2,3}.

Foam dressings have become widely used in the treatment of exuding chronic wounds.

Their high absorption capacity provides better exudate handling, with minimal maceration and leakage⁴. **Biatain** foam dressings are sterile, soft, highly absorbent and conformable polyurethane foam dressings that provide an optimal moist wound healing environment and effective exudate management. **Biatain** foam dressings are protected with semi-permeable film backings that are waterproof and provide bacterial barriers.

Biatain Soft-Hold adhesive foam dressings have a soft, easy to apply, partially adherent layer that enables the dressing to stay in place while a secondary dressing or compression therapy is applied. The adherent layer covers less than 50% of the foam surface, ensuring proper exudate management. The new, improved **Biatain Soft-Hold** offers an even softer and more conformable foam.

Exudate is absorbed locally into the foam pad with minimal lateral dispersal. The backing film provides barrier function whilst allowing evaporation. **Biatain Soft-Hold** have a soft, easy to apply, partially adherent layer, enabling the dressing to stay in place while a secondary dressing or compression therapy is applied or removed. The adherent layer covers less than 50% of the foam surface, thus maintaining superior exudate management for an optimal moist wound healing environment.



MEDICAL HISTORY

The patient is an 82 years old man suffering from a venous leg ulcer on the back of his right leg.

The ulcer had persisted for over three months at inclusion. Prior to inclusion, the ulcer had been treated with hydrocolloid dressings and compression therapy had been applied due to oedema.

Ulcer healing was delayed compared to normally expected healing rate.

On the 23rd of May the patient began treatment with the improved **Biatain Soft-Hold** for one week. The following week the ulcer was treated with the previous version **Biatain Soft-Hold**. Long stretch compression therapy was applied during both weeks. At inclusion the ulcer bed contained more than 60% fibrinous tissue and less than 40% healthy granulation tissue (Figure 1). The ulcer area was measured to 4.9 cm².

WOUND PROGRESS

After one week of treatment with the improved **Biatain Soft-Hold**, the wound bed had improved significantly and the ulcer area was reduced by 35% (Figure 2). At the end of week two, the ulcer area was reduced by 68% and the wound bed had improved and now consisted of 15% fibrinous tissue and 85% healthy granulation tissue (Figure 3). There was continuous wound progress during the entire treatment period (Figure 4).

DRESSING PERFORMANCE

Biatain Soft-Hold supported fast wound healing, markedly reducing ulcer size in just two weeks. The dressing demonstrated advantageous wound bed preparation properties, changing the wound conditions from a majority of fibrinous tissue to mainly healthy granulation tissue. The dressing provided good absorption capacity under the compression therapy and no leakage or maceration was observed. The patient found the dressing comfortable to wear and stated, that the improved **Biatain Soft-Hold** felt softer than the previous and caused less wound pain. The nurse rated the conformability of the improved **Biatain Soft-Hold** good (1 on a 1-3 scale) and perceived it as softer and more flexible than the previous version. Pressure marks were rated as 'none or very vague imprints' and 'vague imprints' with the improved **Biatain Soft-Hold**, consequently outperforming the former version. No adverse events were recorded.

CONCLUSION

During the two weeks treatment period:

- **Biatain Soft-Hold** offered high conformability and easy application.
- **Biatain Soft-Hold** caused no leakage or maceration.
- **Biatain Soft-Hold** provided excellent wound bed preparation properties.
- **Biatain Soft-Hold** demonstrated fast wound healing of this exuding leg ulcer.

In conclusion, the **Biatain Soft-Hold** was found to be a suitable dressing in the treatment of this moderately exuding venous leg ulcer.

REFERENCES

- 1 Gottrup F & Karlsmark T. Ugeskrift for læger 2000;167(7):911-914
- 2 Philips T et al. Journal of the American Academy of Dermatology 1994;31(1):49-53
- 3 Lindholm C et al. Acta Dermato-Venereologica 1993;73(6):440-443
- 4 Thomas S et al. Journal of Wound Care 1997;6(8):383-386

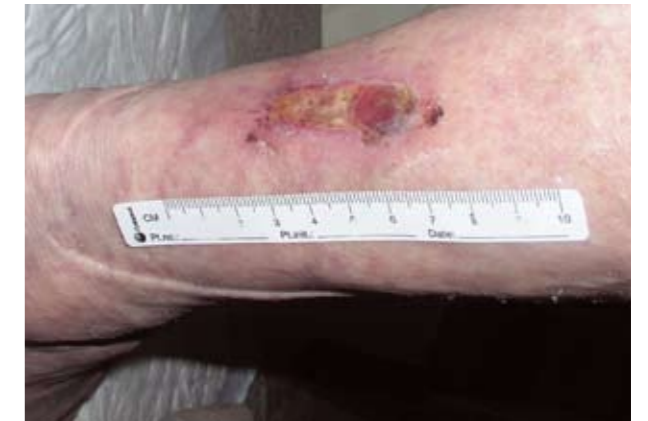

Figure 1 On day three, the ulcer is still dominated by 60% fibrinous tissue.

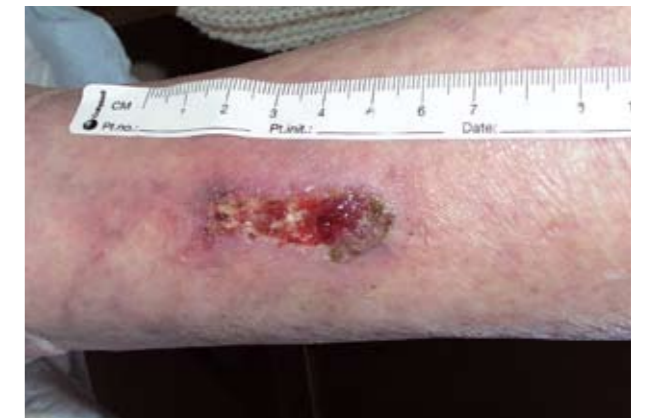

Figure 2 After ten days, the ulcer contains 70% healthy granulation tissue and 30% fibrinous tissue.

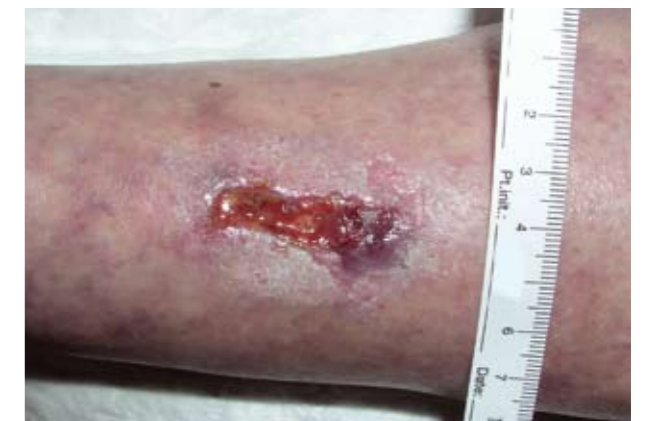

Figure 3 At the end of treatment the ulcer has reduced 68% and is composed of 85% healthy granulation tissue and 15% fibrinous tissue.

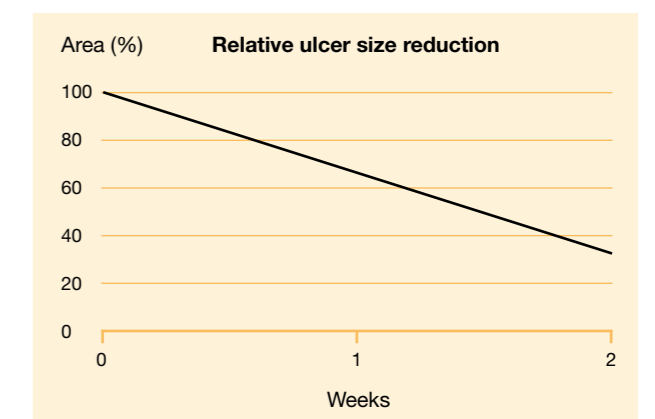


Figure 4 Treatment with **Biatain Soft-Hold** caused improved wound bed conditions and reduction in ulcer size.